

Figure S4. PET/CT guided neck node biopsy.

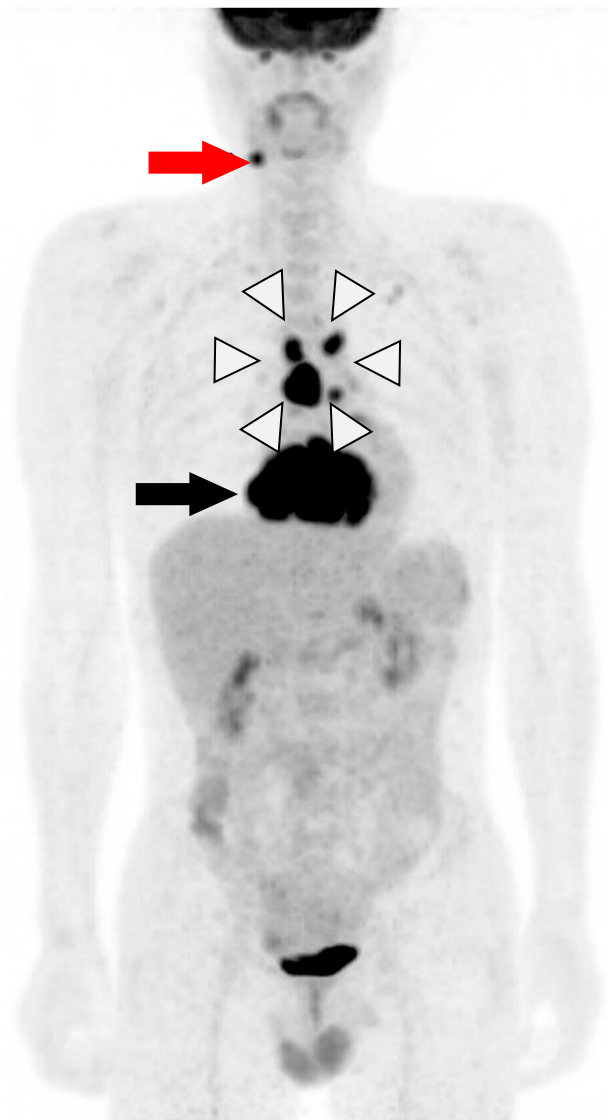


Figure S4. PET image of a primary cardiac lymphoma patient in Maximal Intensity Projection (MIP) view. A hypermetabolic mass involving the right atrium and ventricle of the heart (black arrow), as well as hypermetabolic lymphadenopathy within the mediastinum (white arrowheads) and the right side of the neck (red arrow) were shown. The biopsy was thus taken at the right neck lymph node.